

The logo for LINC (Lifestyle, Nutrition, and Interventional Cardiology) features the letters 'LINC' in a white, sans-serif font. To the left of the text is a stylized graphic consisting of two overlapping, curved shapes in shades of red and orange, resembling a flame or a dynamic motion.

Subacute aorto-iliac occlusion in a young male: “When it rains it pours!”

Bhaskar Purushottam MD

Interventional Cardiologist and Endovascular Medicine

Medical Director, Cardiac Catheterization Lab

Medical Director, Black Hills Cardiovascular Research

Rapid City Regional Hospital, Rapid City, SD

Clinical Assistant Professor of Medicine

Department of Medicine, Sanford School of Medicine

University of South Dakota

Assistant Professor of Cardiology

Idaho College of Osteopathic Medicine

Disclosure

Speaker name:

.....

I have the following potential conflicts of interest to report:

- Speaker for Penumbra Inc.
- Employment in industry
- Stockholder of a healthcare company
- Owner of a healthcare company
- Other(s)

- I do not have any potential conflict of interest

Case Presentation

- 37 y Ex-smoker with a history of alcohol abuse presents to the hospital with one-month history of right lower extremity claudication progressing to rest pain.
- CTA and Ultrasound imaging revealed an occluded right common iliac artery.

Occluded Right Common Iliac Artery

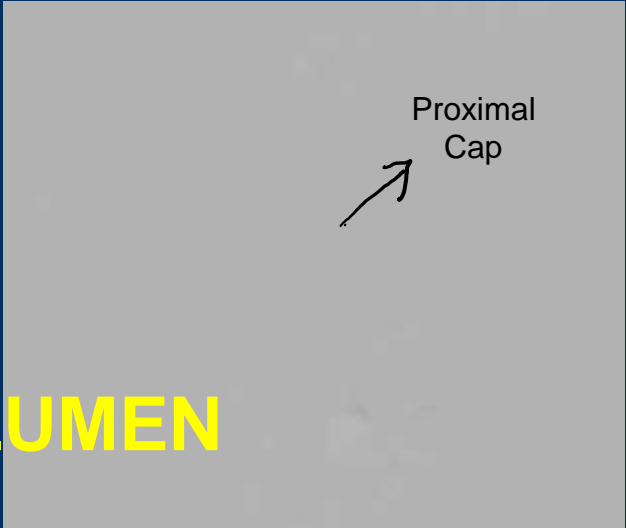


Intervention

Proximal
Cap



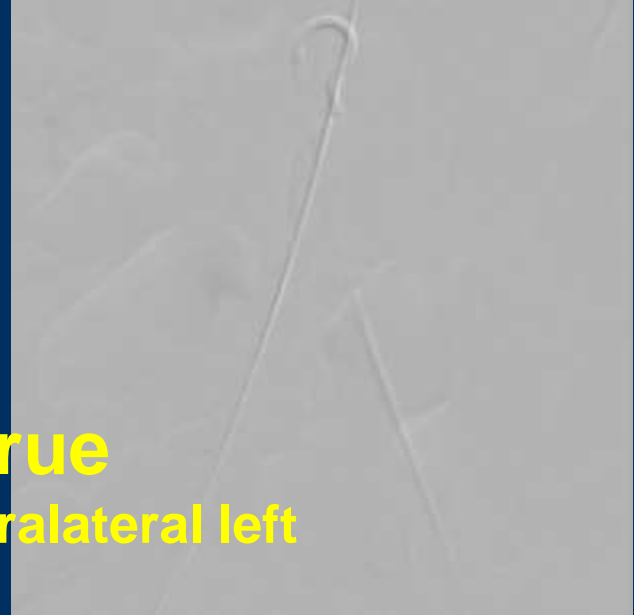
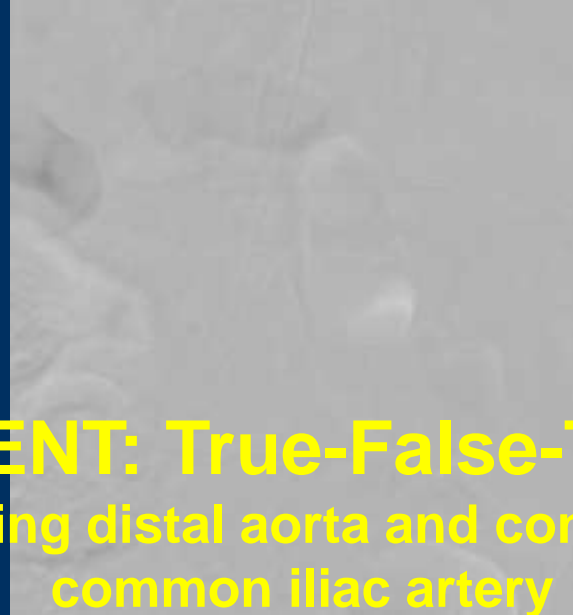Proximal
Cap



WIRE IN THE FALSE LUMEN

STENT: True-False-True

Compromising distal aorta and contralateral left
common iliac artery



Following Day



Right Iliac Limb Is Occluded



Distal Aorta Is Stented
[undersized] and Extended
into the Left Common Iliac
Artery



Fem-Fem Bypass

Three Months Later-Subacute ALI Occluded Distal Abdominal Aorta



Extensive Occlusion

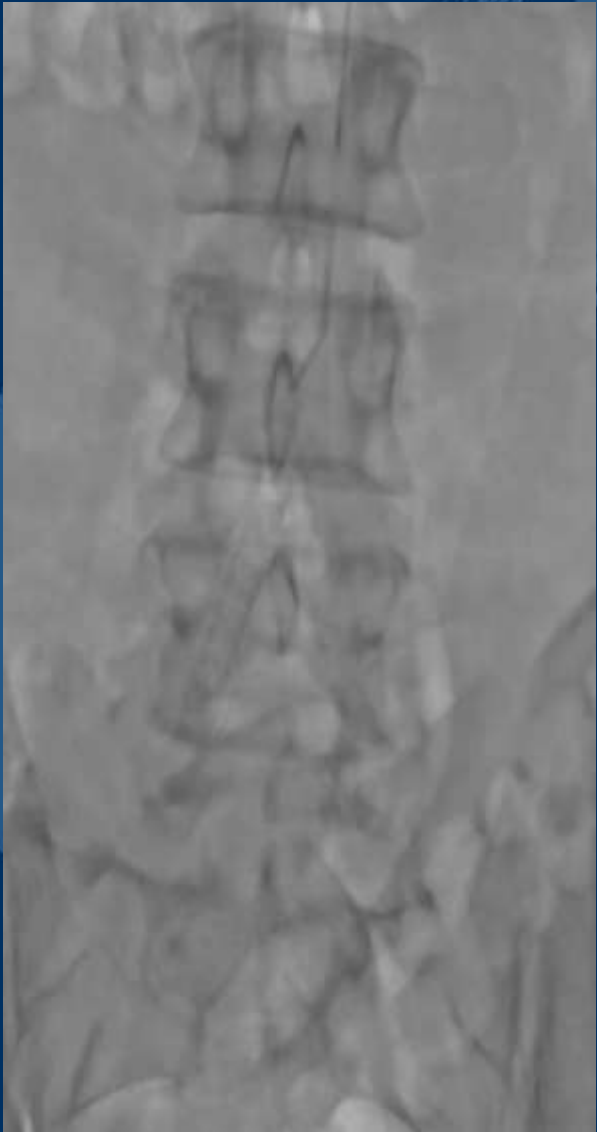

**No Flow in the Right Lower
Extremity Arterial System**



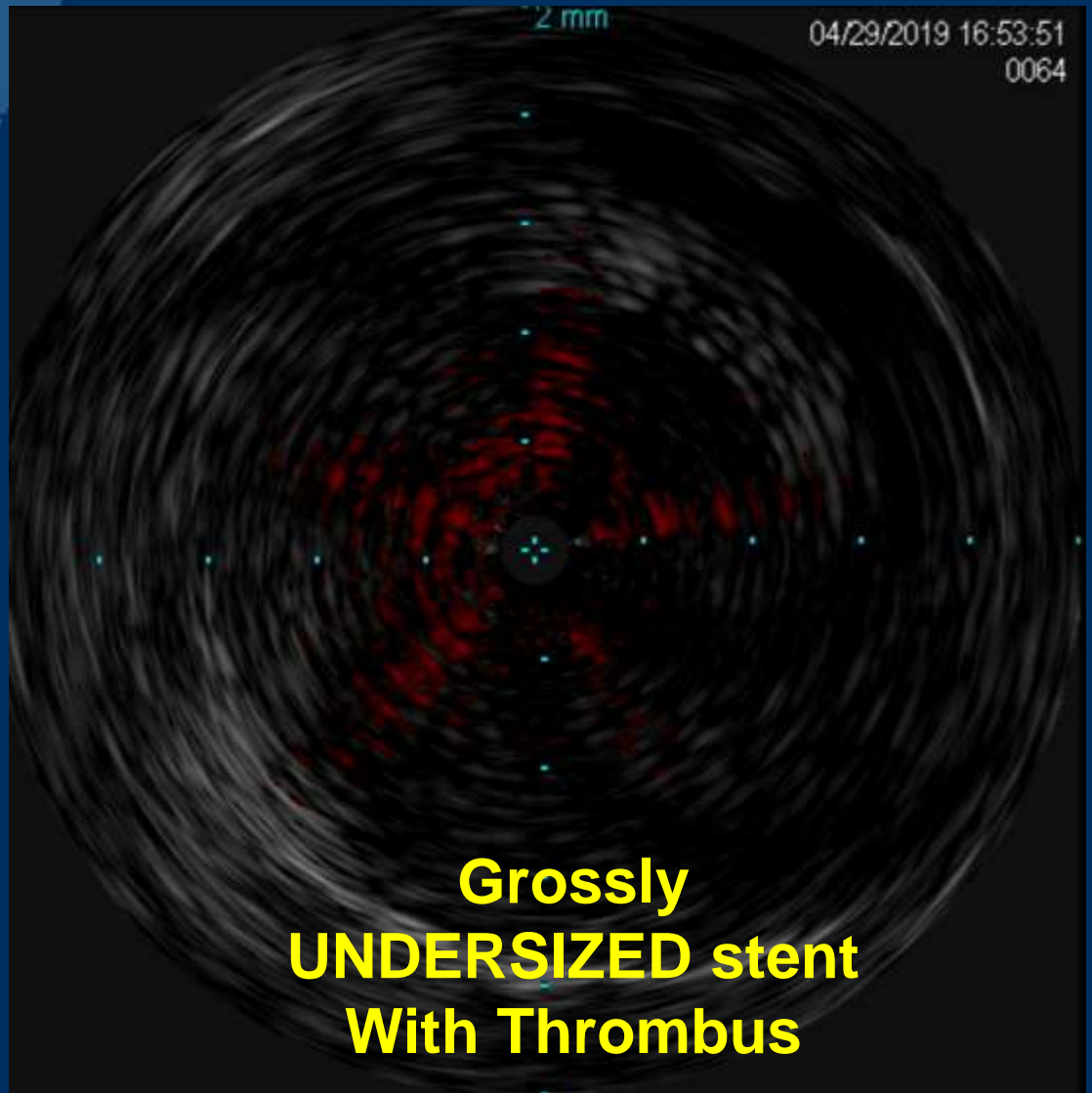
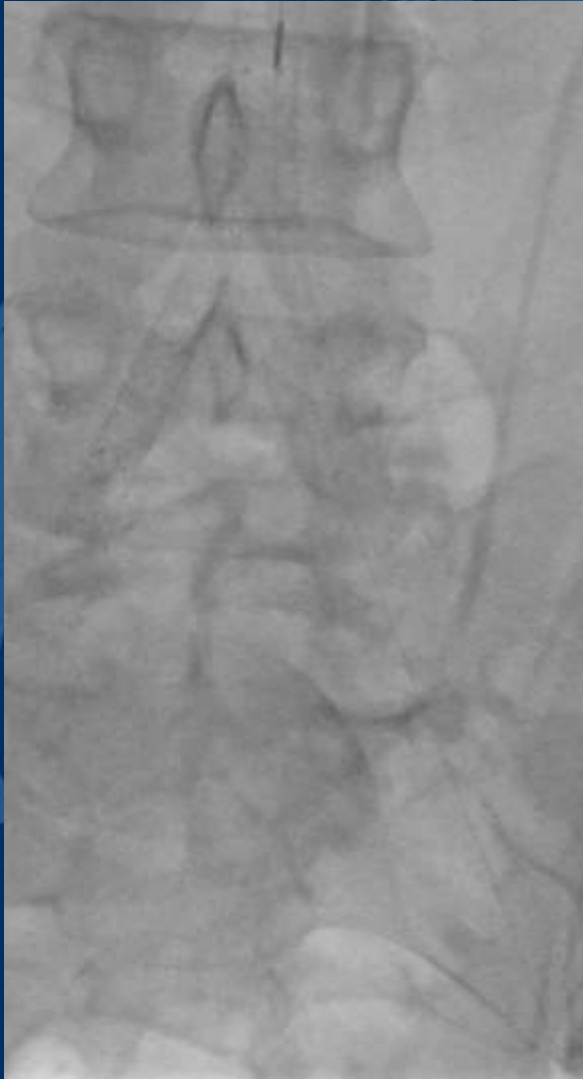**Very Slow Flow in the Left
Lower Extremity Arterial System**



Crossing the Occlusion: Left Brachial Approach

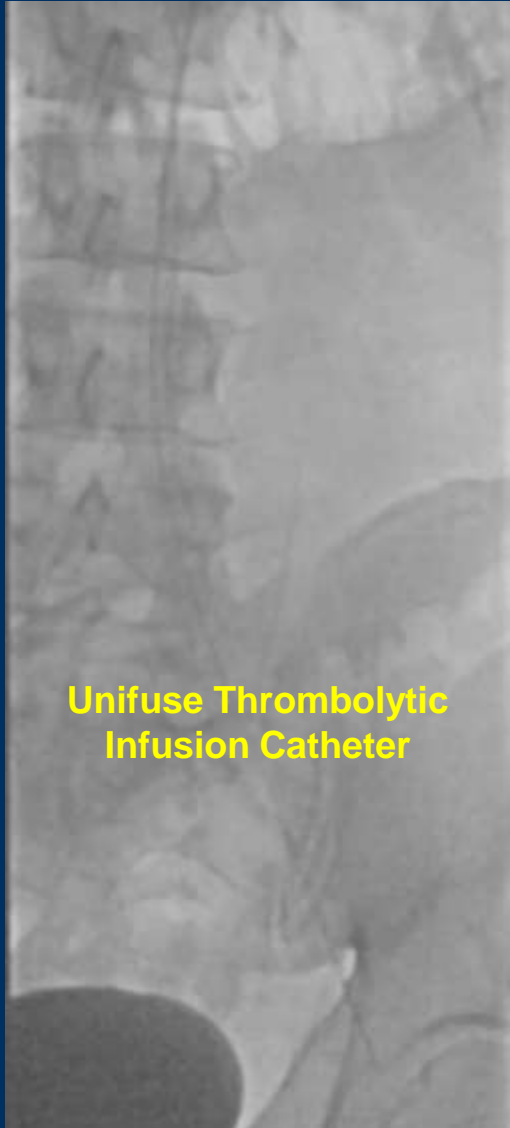
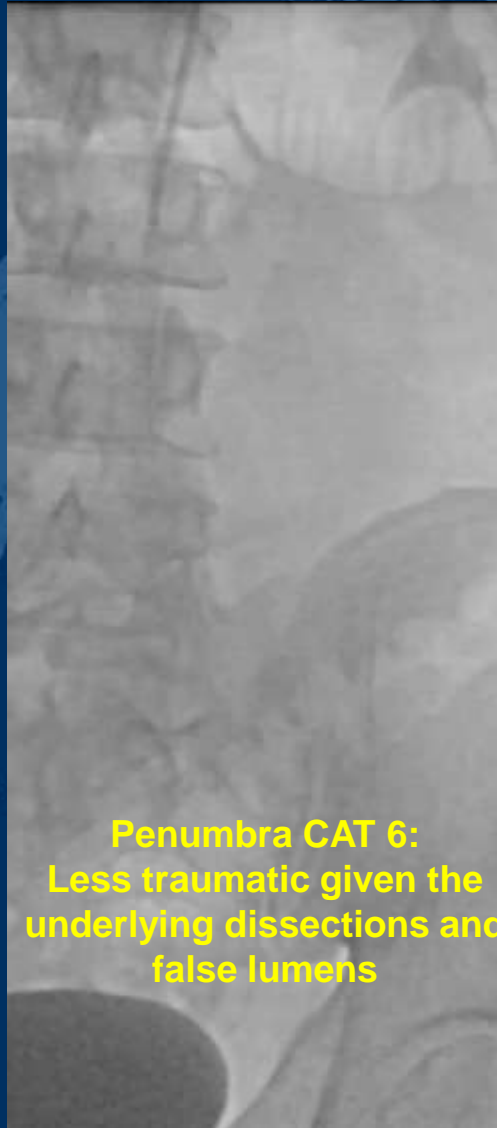

Intravascular Ultrasound



**Grossly
UNDERSIZED stent
With Thrombus**

Thrombectomy followed with CDT



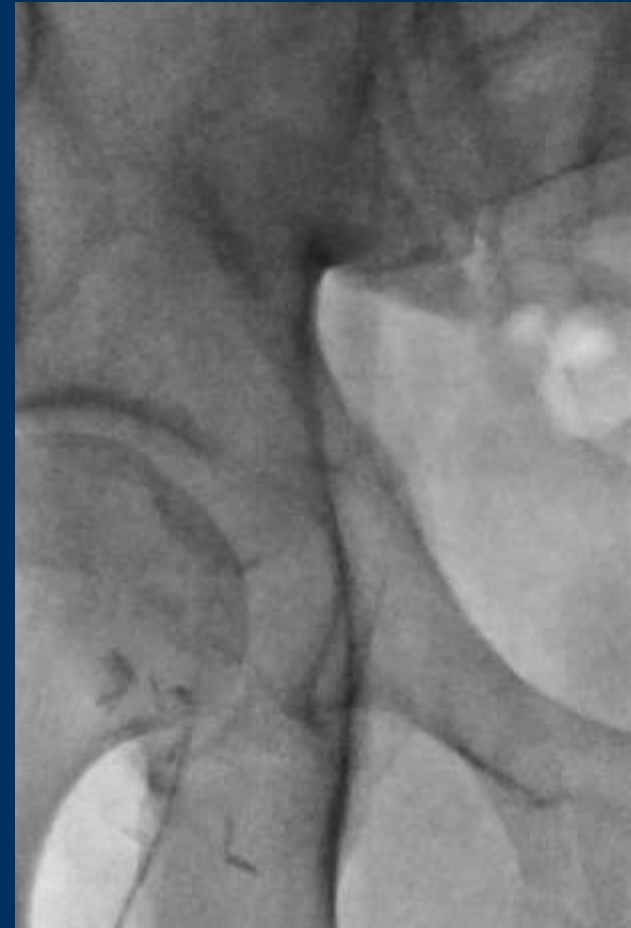
Following Day



Significant Improvement



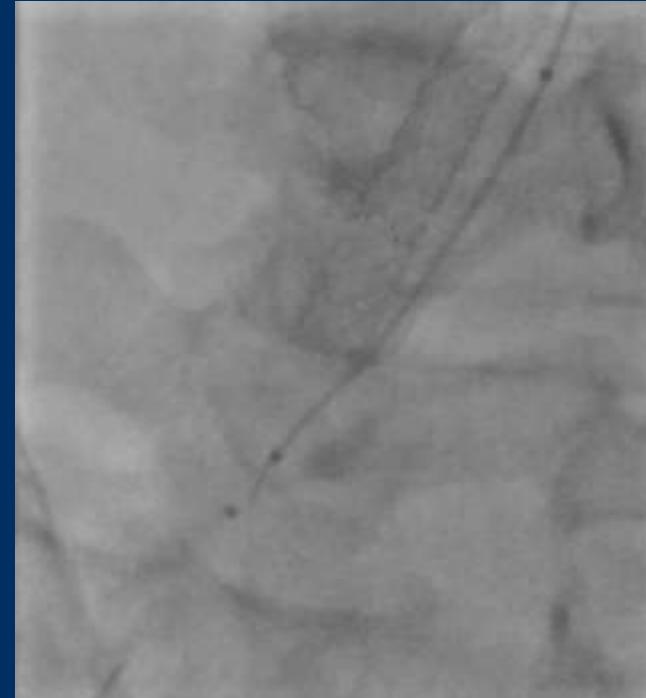
Right CFA Access



Crossing the Right Iliac Arterial System



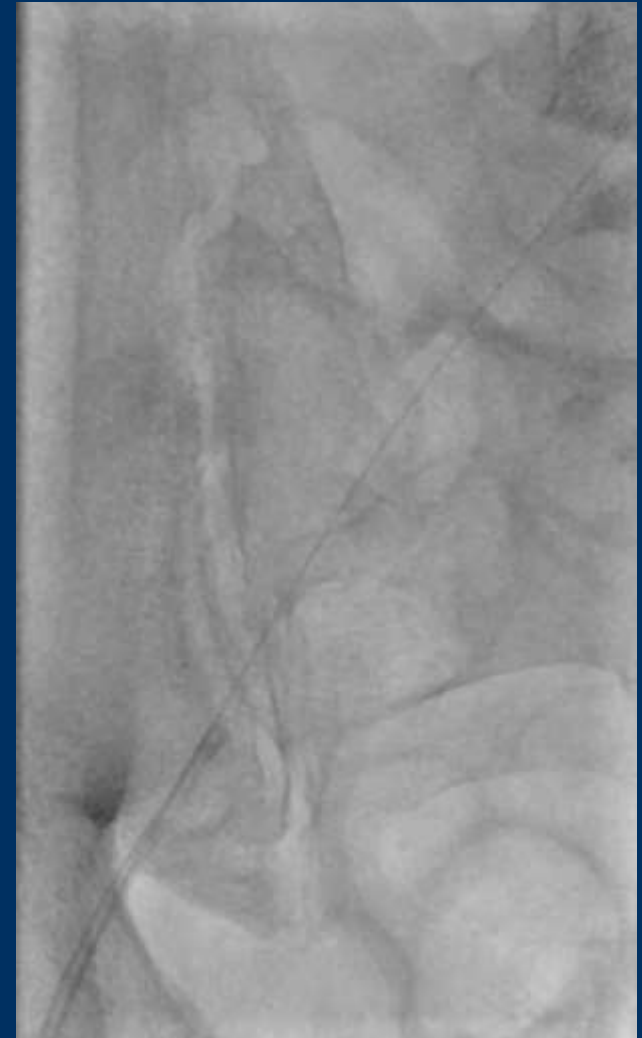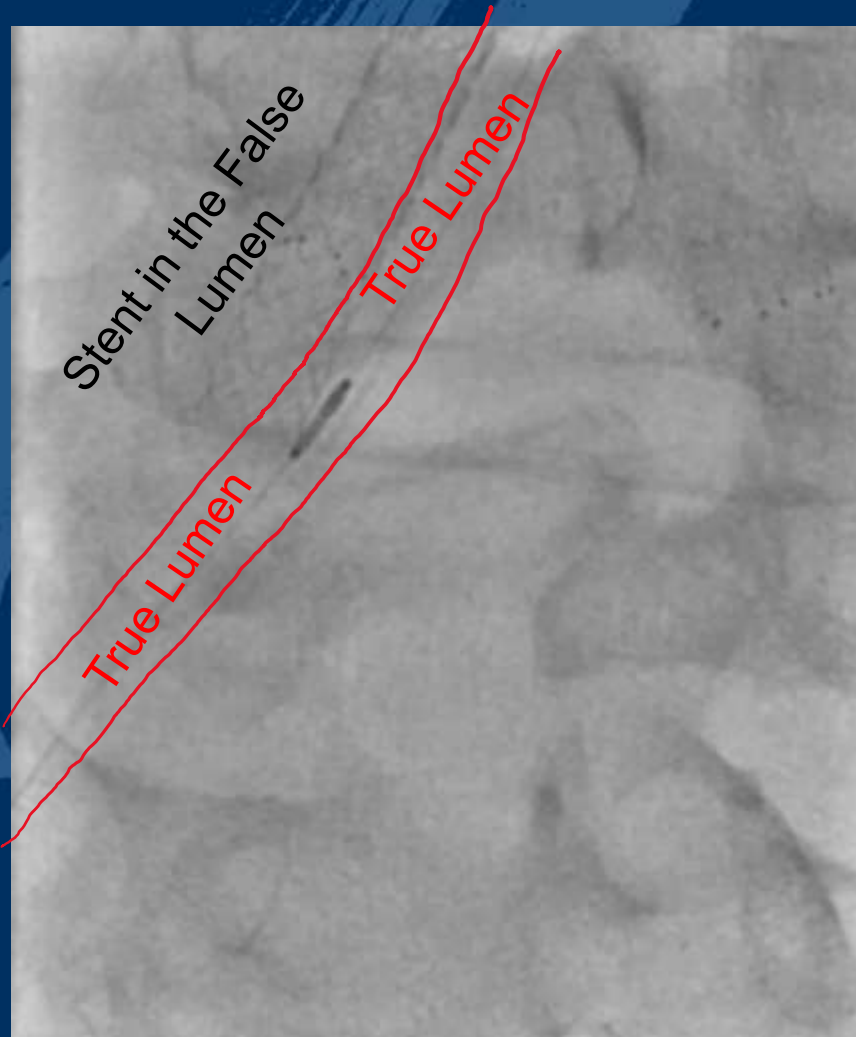
**Multiple Dissection Planes
Making the Cross Difficult**



**Multiple Dissection Planes
Making the Cross Difficult**

**Crossed from the
Cranial End**

IVUS and Aspiration Thrombectomy

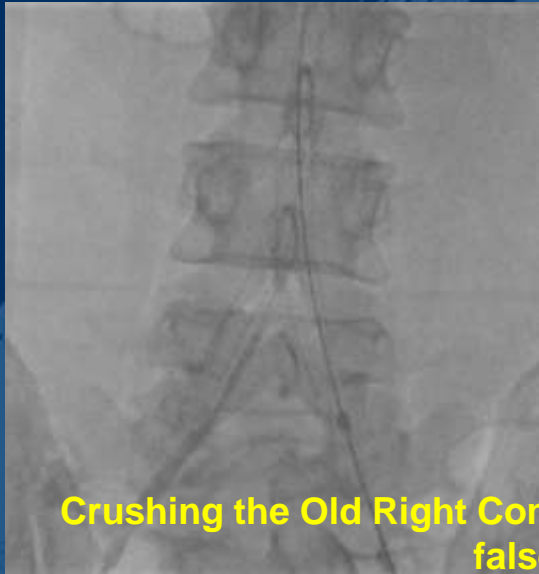

Post Aspiration Angiograms

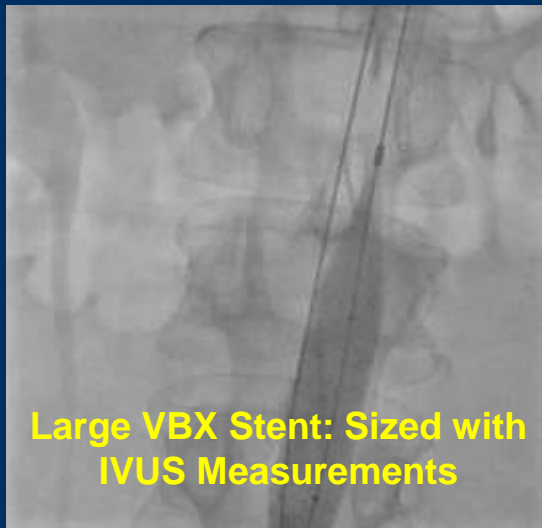
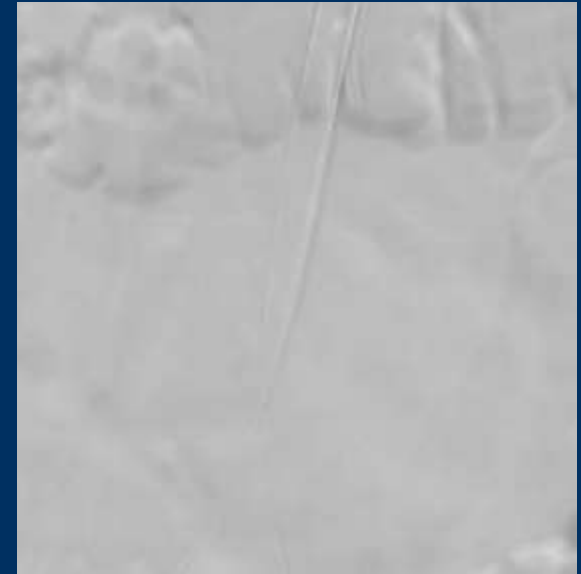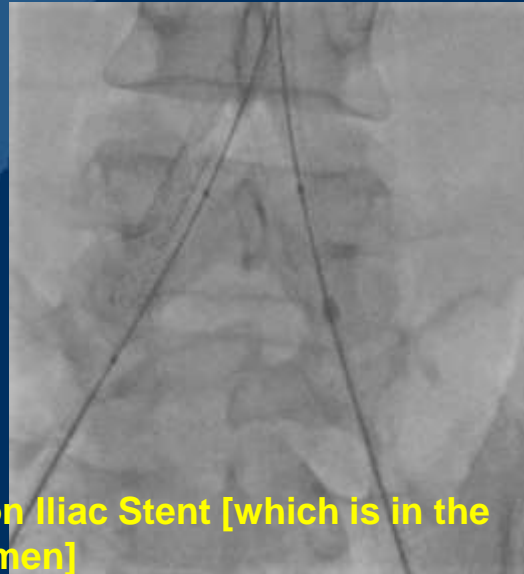
3

**Retrograde Distal Abdominal Aortic
Dissection
And
Residual Thrombus**


Covered Stenting of the Distal Aorta and Iliac Limbs



Crushing the Old Right Common Iliac Stent [which is in the false lumen]

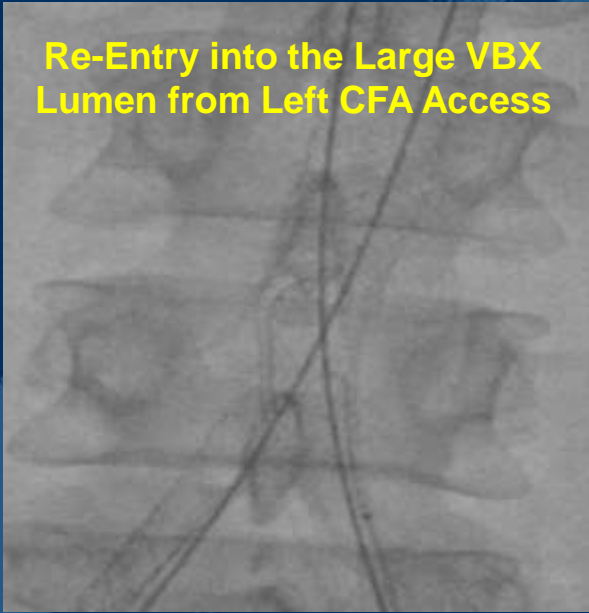


Large VBX Stent: Sized with IVUS Measurements

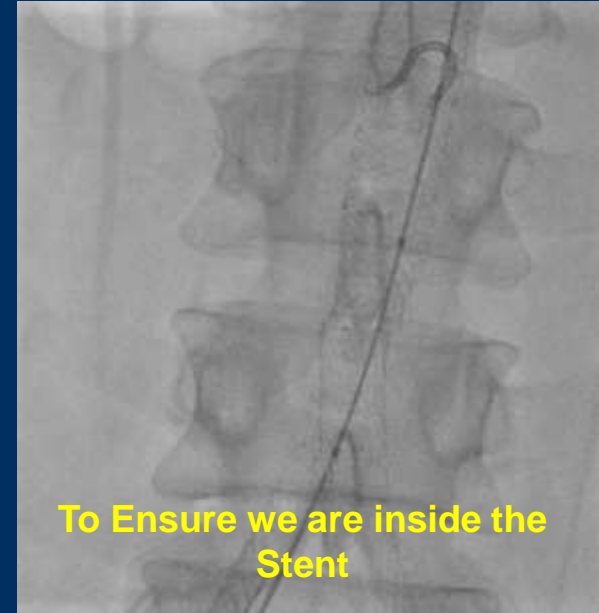


Kissing VBX Stents into the Main VBX

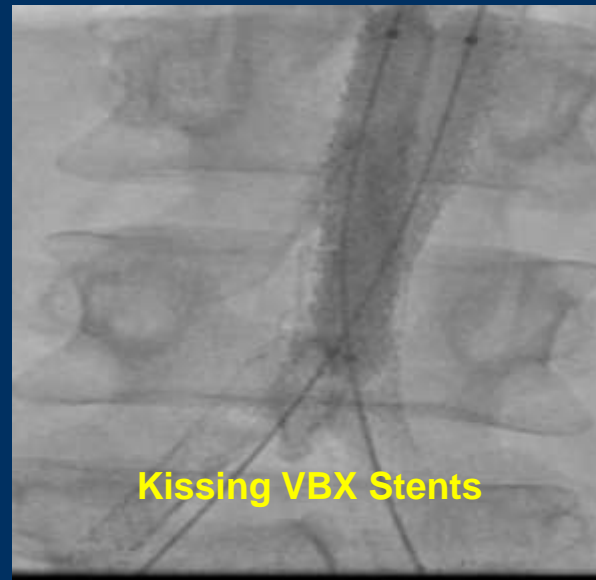Re-Entry into the Large VBX Lumen from Left CFA Access



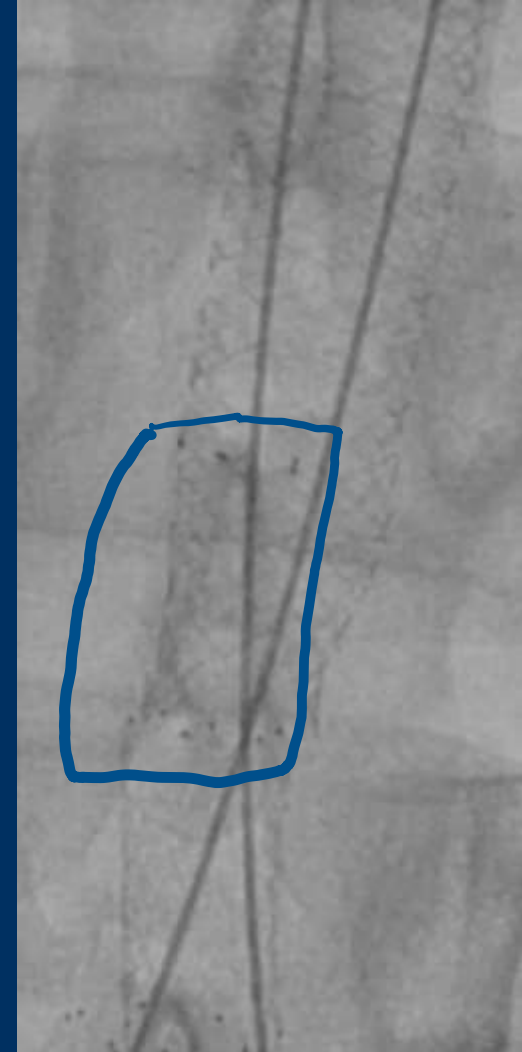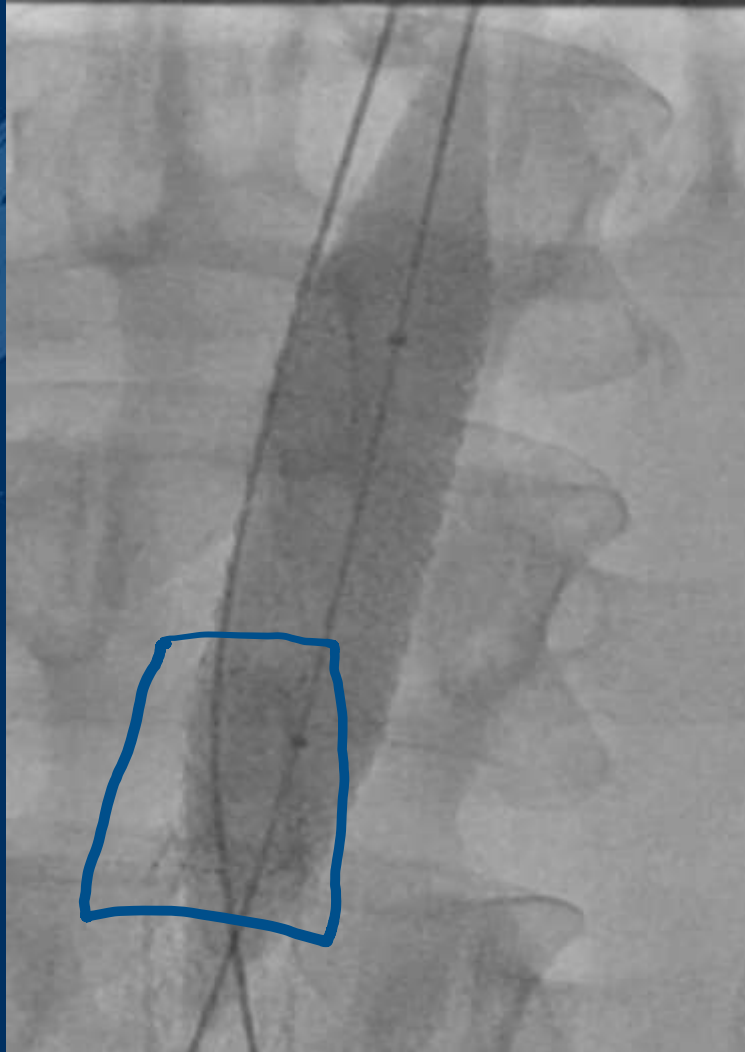
To Ensure we are inside the Stent



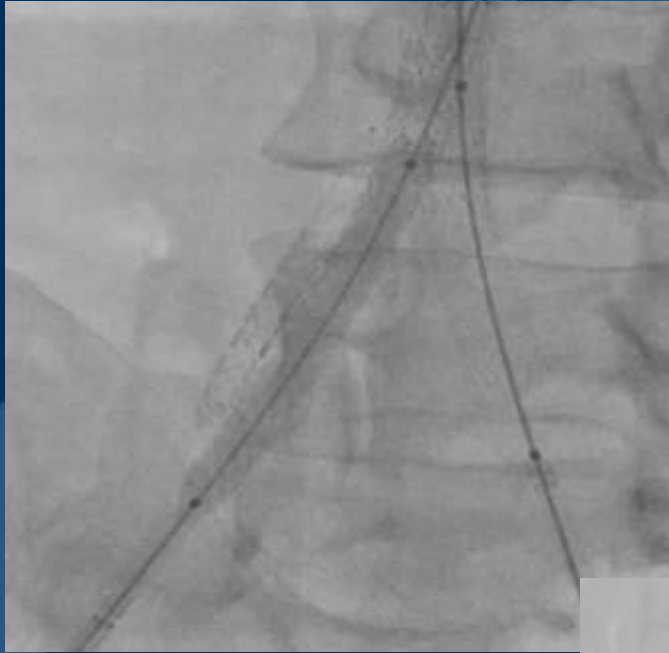Kissing VBX Stents




Crushing the Old Stent



Covered Stenting of the Right Iliac Arterial Tree



Final Angiograms



- Total of 210 cc of contrast
- No Periprocedural complications
- Made a steady recovery and discharged two days later
- Placed on Xarelto, Plavix and high dose Statin
- Paroxysmal Atrial Fibrillation noted with a normal echocardiogram
- Follow-up imaging shows patent arteries
- Patient is back to work [construction worker]

LINC

Subacute aorto-iliac occlusion in a young male: “When it rains it pours!”

Bhaskar Purushottam MD

Interventional Cardiologist and Endovascular Medicine

Medical Director, Cardiac Catheterization Lab

Medical Director, Black Hills Cardiovascular Research

Rapid City Regional Hospital, Rapid City, SD

Clinical Assistant Professor of Medicine

Department of Medicine, Sanford School of Medicine

University of South Dakota

Assistant Professor of Cardiology

Idaho College of Osteopathic Medicine



Thanks

Subacute aorto-iliac occlusion in a young male: “When it rains it pours!”

Bhaskar Purushottam MD

Interventional Cardiologist and Endovascular Medicine

Medical Director, Cardiac Catheterization Lab

Medical Director, Black Hills Cardiovascular Research

Rapid City Regional Hospital, Rapid City, SD

Clinical Assistant Professor of Medicine

Department of Medicine, Sanford School of Medicine

University of South Dakota

Assistant Professor of Cardiology

Idaho College of Osteopathic Medicine