

The LINC logo features a stylized graphic of a red and orange flame or ribbon shape above the letters "LINC" in white.

LINC



# Video Live and Lecture

**Hiroshi Ando, MD**

**Heart Center, Limb Salvage Center  
Kasukabe Chuo General Hospital  
Saitama, Japan**



ITABASHI MEDICAL SYSTEM

# Disclosure

Speaker name: Hiroshi Ando

I have the following potential conflicts of interest to report:

- Consulting
- Employment in industry
- Stockholder of a healthcare company
- Owner of a healthcare company
- Other(s)
  
- I do not have any potential conflict of interest

# Case: Female 82y.o.

---

**Rt. ATA, PTA, PeA, DPA, Plantar A occlusion**

Clinical data:

PAOD, Rutherford 5, Rt. III, IV, V toe ulcer

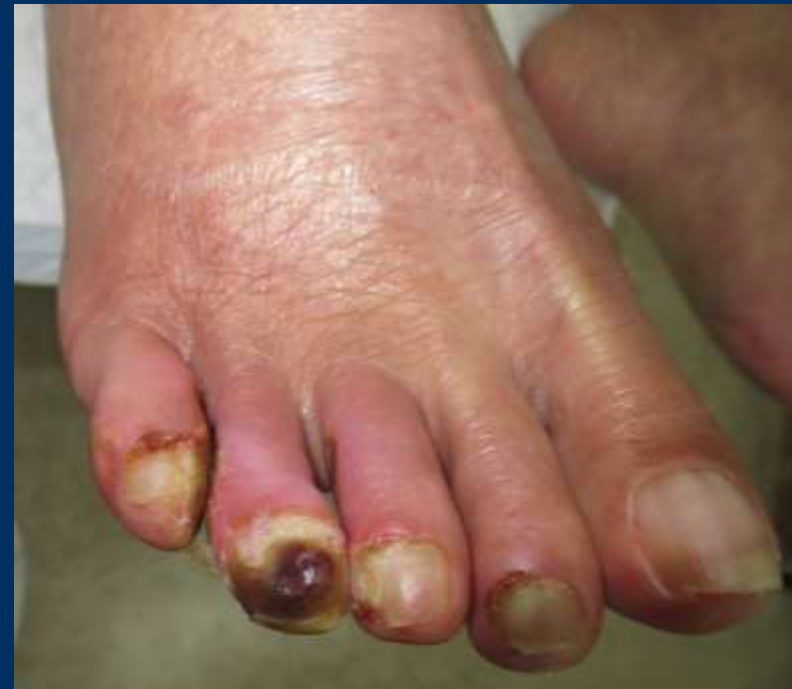ABI: unmeasurable

SPP: Rt. D N/A / P 58mmHg

old CVD

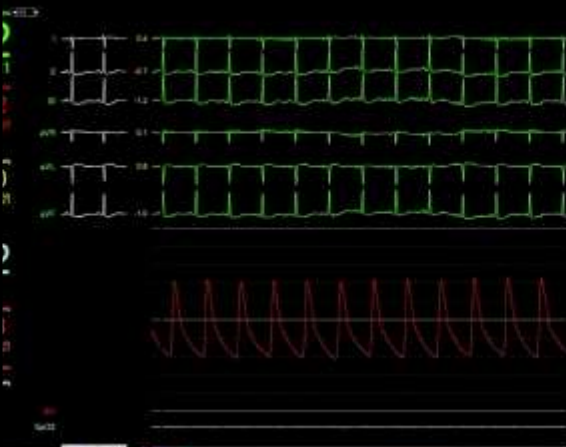
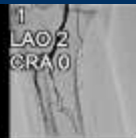RA

Hypothyroidism



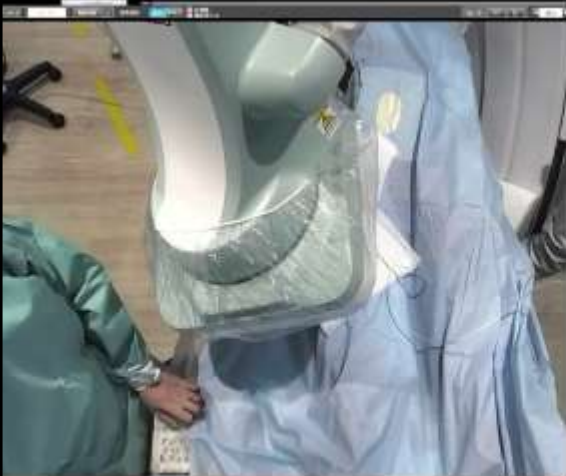00405449 Case 2  
2019/12/21 09:50:37

**RSM**



mGy  
**6.6**  
mGy/min  
**0.0**  
mGym2  
**0.081**

RAO  
**27**  
CRA  
**0**  
SID  
**95**  
FOV  
**6.0**




Fluo(min)  
**1.1**

I-T(s)  
**0.0**

LIVE

Peri / RSM[7f-45s]  
Peri / 7.5pps/Low

*Where there's a will there's a way !*



**Thank you for your attention**

The LINC logo features a stylized graphic of a red and orange flame or ribbon shape above the letters "LINC" in white.

LINC



# Video Live and Lecture

**Hiroshi Ando, MD**

**Heart Center, Limb Salvage Center  
Kasukabe Chuo General Hospital  
Saitama, Japan**



ITABASHI MEDICAL SYSTEM